



**Dr.RAKESH GUPTHA**

**Alcohol Intoxication - An Emergency With An Extra Ocular Muscle Paralysis And its Homoeopathic Management.**

**Dr Rakesh Gupta<sup>1</sup>, Yarish Sadri<sup>2</sup>, Sayli Shinde<sup>3</sup>**

<sup>1</sup>HOD and Associate Professor, Forensic Medicine and Toxicology, Chandaben Mohanbhai Patel Homeopathic Medical college, Mumbai, Senior Medical officer and Homoeopathic Consultant at Shree Mumbadevi Homoeopathic Hospital. Mumbai.

<sup>2</sup> 3rd year BHMS, Smt Chandaben Mohanbhai Patel Homeopathic Medical college, Mumbai, India

<sup>3</sup>3rd year BHMS, Smt Chandaben Mohanbhai Patel Homeopathic Medical college, Mumbai.India

**\* Corresponding author:** Dr Rakesh Gupta, HOD and Associate Professor, Forensic Medicine and Toxicology, Smt Chandaben Mohanbhai Patel Homeopathic Medical College, Mumbai, India

**Abstract:** Alcohol consumption is gradually increasing worldwide. There are numerous cases which report to various hospitals with acute psychiatric emergency as well as neurological presentation. This case demonstrates the role of Homeopathic medicines in the treatment of Alcohol induced Neuro-Psychiatric manifestations. Effective utilization of the Evolutionary Psycho dynamic understanding of the personality helps in correct homoeopathic remedy prescription.

**Key words:** *Alcoholism, substance abuse, suicidal attempts, Right lateral rectus palsy, diplopia, Conium*

**Introduction:** - This case is a unique case suffering from both mental and physical derangement due to alcohol indulgence. Alcohol induced mono neuropathy has resulted in right lateral rectus muscle palsy leading to Diplopia due to failure of right eye lateral rotation.

Alcohol intoxication with behavioural derangement resulting in suicidal attempts was efficiently treated with the correct similimum, isolation and patient counselling. The conventional line of treatment would administer multivitamins and steroids in order to treat the right rectus palsy but it was completely managed with the help of Homoeopathic medicines without any steroids.

**Case History:** A 32-year-old female who is a chronic alcoholic since many years had presented with an episode of binge alcohol drinking since morning. Relative made a telephonic call in the evening stating that patient has injured herself (self inflicted incised wounds) with a knife under the alcohol influence and also there were constant hiccoughs. She also had complaints of Diplopia (double vision); Vertigo and Photophobia which were better by closing her eyes<sup>2+</sup>.

On observation in the hospital: **UNDER ALCOHOL INFLUENCE:**

She was in the state of psychomotor agitation, abusing, violent anger, refusing to take treatment, shouting at others, Breath holding spells and injuring herself.

Figure no 1: Multiple Incised cuts on the left forearm (Hesitation or Suicidal cuts) inflicted by the patient.

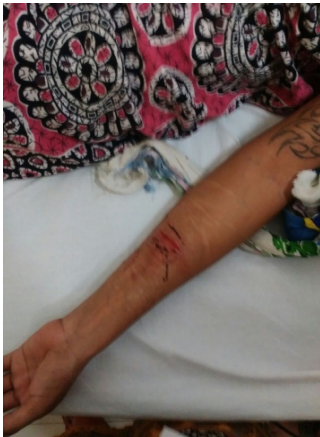

Figure 2: Right Lateral Rectus Palsy with staring look and puffiness of the lids.



O/E: CLW (2 x 1/ 2 cm) on left forearm. BP – 150/100 mm Hg, P – 130/ min

RS/CVS/PA- NAD, CNS- Reflexes- B/L equal, Pupils- Dilated

MACEWAN'S SIGN- Negative, (In case of alcohol intoxication, pupils are contracted, but on external

painful stimulation e.g., by pinching on the same side of the eye causes pupil to dilate followed by slow constriction again. this is called as Macewan's sign and if this is positive, it is suggestive of alcohol poisoning and intoxication alcoholic or encephalopathy).

#### Mental Status Examination at the time of admission

- Appearance- poorly groomed, hesitation cuts on hand, alcoholic smell
- Behaviour - Catatonic Posture (it is a state of Psycho-motor immobility and behavioural abnormality manifested by stupor).
- Orientation- Disoriented to time, place and person
- Speech- Abrupt, Incoherent speech
- Insight/ Judgment – Poor, Grade zero

Life situation: 32-year woman during the interview stated that she lost her father at an early age of 5 years, yet had a pleasant and pampered childhood. Her bringing up was done by her elder brother and mother. The mother was illiterate and got her married at an early age of 15 years. The patient delivered a child within a year after marriage. After the birth of a child, her husband left her and child. She has been a single mother for the past 15 years. There is lot of stress and sadness

which made her dependent on Alcohol. There is complete disintegration of her personality.

She has become abusive, violent, and is harming herself. She is unable to share her feelings with anyone and is reserved. She is been deprived of any form of sexual contact for the last 15-16 years since her husband has left her. She stated that she requires physical love which she cannot get because husband is not there. She is drinking alcohol and tried committing multiple suicidal attempts. The physical symptom of right abducens nerve palsy has also developed due to Constant alcohol abuse. She had Dreams of being pursued by Enemies.

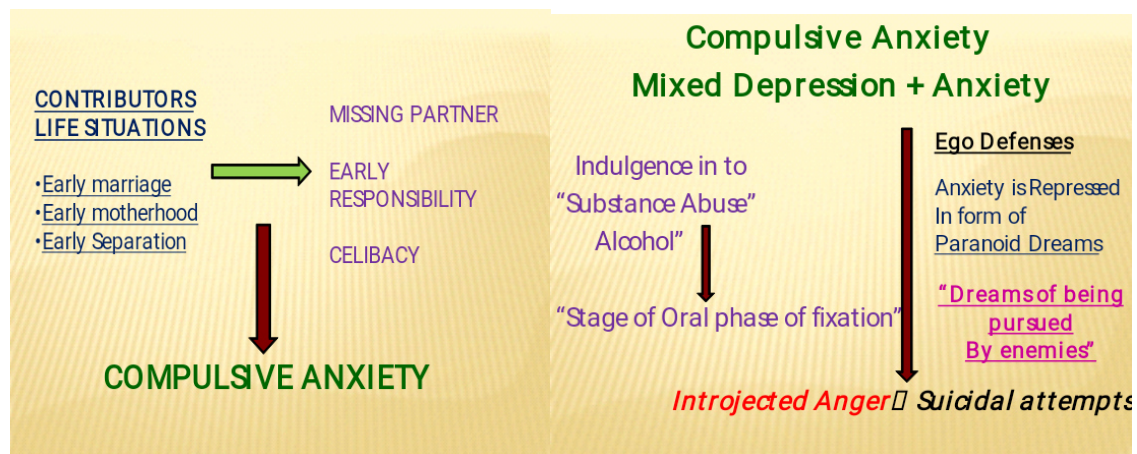
Investigations: Hb- 13.2 WBC- 8400 ESR- 47 RBS- 68 LFT- Normal S.CREAT – Normal Urine routine:- Pus cells- 12-15/hpf

**DIAGNOSIS: ACUTE ALCOHOL  
INTOXICATION, SUBSTANCE ABUSE  
(ALCOHOLISM) WITH SUICIDAL ATTEMPTS  
and RIGHT ABDUCEN NERVE PALSY.**

Hahnemannian CLASSIFICATION OF DISEASE:  
Acute on Pseudo Chronic (Aphorism no 77) with

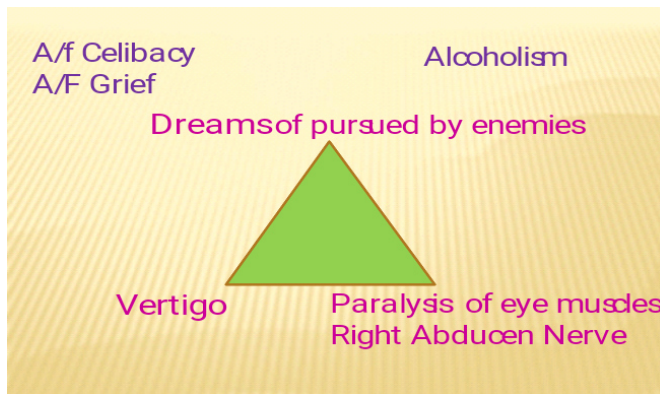
Secondary Dynamic disease with fully developed symptoms

Fig 3: PSYCHO DYNAMIC UNDERSTANDING AND DREAM INTERPRETATION



She has repressed and suppressed her emotions. Her repressed feelings are expressed in dreams of being pursued by enemies. “Enemies” is symbolic representation of “Threat” (Threats are Her Realities, Husband who abandoned her) “She is running to protect herself”. This is CONTRARY To her conduct “One Hand She dreams of threat and trying to survive”&Other Hand She harms her own self. This contrary behaviour becomes an important theme of the case. On the other hand there is somatisation of her psychological state in form of right rectus muscle palsy.

**Fig 4: PRESCRIPTIVE TOTALITY**



**Fig 5 : REPORTORISATION**

RADAR 10.0 for Windows

Investigation window for remedies

Clipboard 3

1. MIND - ALCOHOLISM (149) 1
2. MIND - AILMENTS FROM - celibacy (13) 1
3. VERTIGO - CLOSING eyes, on - amel. (22) 1
4. EYE - PARALYSIS - Muscles of eyeball (28) 1

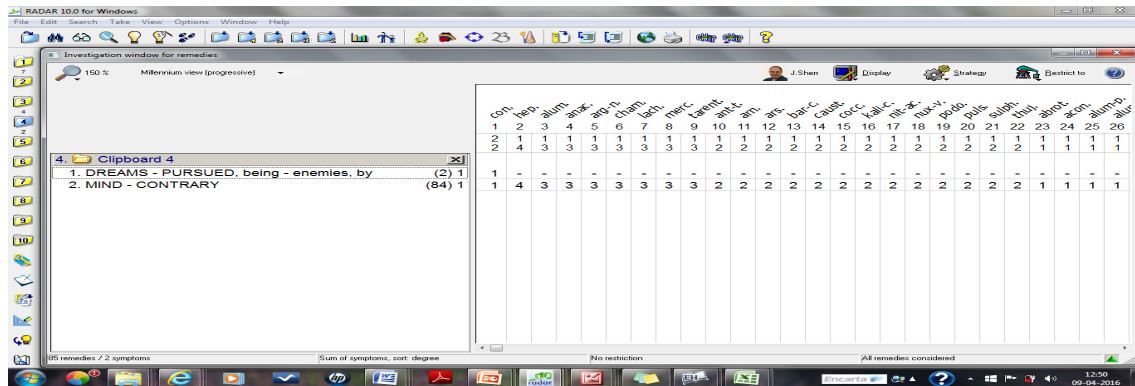
	con.	allim.	gels.	phos.	caust.	akom.	sepi.	ruks-v.	nat.m.	rhuis-t.	sel.	syrph.	asair.	aur.	calc.	camp-l.	chiel.	corr.	ferr.	graph.	hyos.	kr.	spib.	sulph.	agn.	am.	bulfo.	dig.	fl-ak.	kali-i.	plat.	puls.	rutu.	samo.	agar.	chin.	crot-h.	can-b.	verat.	abain.	ant.c.	
1	2	3	4	5	6	7	8	9	10	11	12	13	14	15	16	17	18	19	20	21	22	23	24	25	26	27	28	29	30	31	32	33	34	35	36	37	38	39	40	41	42	
4	4	3	3	3	3	3	2	2	2	2	2	2	2	2	2	2	2	2	2	2	2	2	2	2	2	2	2	2	2	2	2	2	2	2	2	2	2	2	2	2	2	2
7	4	8	6	5	4	4	5	4	4	4	4	3	3	3	3	3	3	3	3	3	3	3	3	2	2	2	2	2	2	2	2	2	2	2	2	2	2	2	2	2	2	2
1.	1	1	2	2	1	1	2	2	2	2	3	3	2	2	2	1	2	2	2	2	2	2	2	2	1	1	1	1	1	1	1	1	1	1	1	1	1	1	1	1	1	1
2.	1	1	-	3	1	-	1	-	-	-	-	-	-	1	2	-	-	-	-	-	1	-	-	1	-	-	-	1	-	1	-	-	-	-	-	-	-	-	-	-	-	-
3.	3	1	3	-	-	1	1	-	-	-	1	-	1	-	-	-	-	1	1	-	-	1	-	1	-	-	1	-	1	-	1	-	-	-	-	-	-	-	-	-	-	-
4.	2	1	3	1	3	2	-	3	2	2	-	1	-	1	-	-	1	1	-	1	-	1	-	-	1	-	1	-	1	-	1	-	-	-	-	-	-	-	-	-	-	-

163 remedies / 4 symptoms      Sum of symptoms, sort: degree      No restriction      All remedies considered

07:55 09-04-2016



Fig 6: REPORTORISATION



## Differentiation of remedies

<u>SYMPTOMS</u>	<u>Alumina</u>	<u>Ignatia</u>	<u>Conium</u>
MIND	Depressed as with grief. Anxiety, with external heat and uneasiness as if she had done something bad. Extremely peevish and obstinate. Frequently changing mood .Dullness of mind. Serious, anxious mood	Anxiety, as if he head committed some crime. Dread of every trifle, especially of things coming near him.Indifferent to everything. Fear of thieves. Dreams the whole night of one and the same thing with dreams of frightful things.	Drunkenness. The slightest spirituous drink intoxicates him; even watered wine rises to his head.Averse to being near people, inclined to seize hold of and abuse them.Anxious dreams full of threatening dangers. Hypochondriac depression and indifference
EYES	Squinting of both eyes.	Dimness of vision of the right eye. Painful pressure above the eyes, especially on looking at the light	Double vision for several minutes, The absence of action of the muscles supplied by the fourth and six pairs of nerves.
<u>PHYSICALS</u>		Intoxication- Beer rises easily to the head and causes intoxication.	

## CONIUM Remedy:

KENT'S MATERIA MEDICA	PHATAK MATERIA MEDICA	CLARKE'S MATERIA MEDICA
<p>Mental symptoms, nervous symptoms, trembling, in widows and widowers who have suddenly been deprived of their sexual relations.</p> <p>persons who have suffered from grief, they become broken in memory</p> <p>He is averse to being near people and to talking of those passing him; is inclined to seize hold of and abuse them.</p> <p>Paralysis of muscles of the eyes.</p>	<p>Hypochondriasis from sexual abstinence or sexual excess</p> <p>Depressed, timid, averse to society, yet fears being alone</p> <p>Periodical insanity, of alternating type.</p> <p>Easily intoxicated</p> <p>Worse- alcohol</p> <p>Affects nerves, muscles causing inco-ordination and paralysis.</p> <p>Diplopia</p>	<p>Hysterical anguish from suppression of the sexual instinct .</p> <p>Anthropophobia, yet fear of solitude.</p> <p>Hypochondriacal indifference, Disposition to be angry.</p> <p>Intoxication after taking smallest quantity of spirituous liquid.</p> <p>Diplopia with photophobia.</p> <p>Dreams of Danger.</p>

## FOLLOW UPS


Fig 7 At the start of the treatment:- Conium 200 first dilution for 2 days.

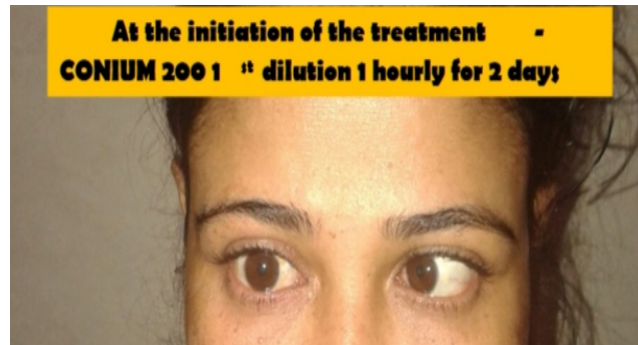

Fig 8: After 2 days of treatment

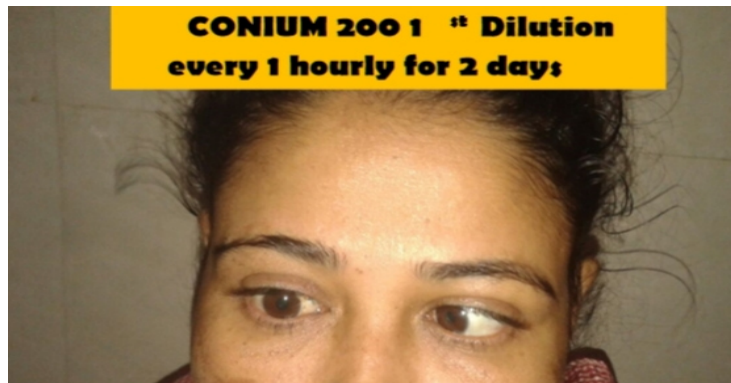

Fig 9: After 4 Days of the treatment.



### **Conclusion:-**

1. Identifying the correct Similimum is based on detail evolutionary history of the patient.
2. Psychodynamic and psychosomatic co-relation often helps in totality construction which ultimately leads to right Similimum
3. Dream analysis and co-relation with current psychological understanding leads to therapeutic planning and remedy selection.
4. Understanding the Cause and Effect relationship during the case taking and case processing.
5. Neurological Disorders requires careful and close monitoring during the course of treatment with documented evidences.

## **Acknowledgement: -**

We thank to Dr Mohanbhai Patel, Chairman, The Homoeopathic Education Society (Smt. Chandaben Mohanbhai Patel Homoeopathic College), Dr Asmita Parikh; General Secretary, The Homoeopathic Education Society (Smt. Chandaben Mohanbhai Patel Homoeopathic College) and Dr Parizad Damania-Principal, Smt. Chandaben Mohanbhai Patel Homoeopathic College for the encouragement, support and hospital infrastructure.

## **References:-**

1. Anand. R. Kapse, I.C.R. Operational Manual, Dr M.L.Dhawale Memorial trust, Mumbai, 2003, Page 69 -102.
2. S.R. Phatak, Materia Medica of Homoeopathic medicines, B.Jain Regular, Second Edition, Jun 2007 page 255-259
3. Hahnemann S, Organon of medicine, 6<sup>th</sup> edition, New Delhi: Birla publication 2003 (aphorism246 page number 270-271)
4. Radar opus computer program. Version 10.5, Belgium 2012.
5. J.T. Kent, Lectures On homoeopathic Materia Medica, B Jain Publishers Pvt Ltd, new Delhi,

2002, 12<sup>th</sup> Impression: 2014, Page no 467 – 473.

6. Allen T.F., Encyclopaedia Of Pure Materia Medica, B Jain Regular, 1981, page 411-419.
7. J.H. Clarke, Dictionary of Practical Materia Medica, B Jain Publishers Pvt Ltd, 1994, page 581-589.
8. Ramanjit Sihota, Radhika Tandon, Parsons' Diseases of the Eye, Reed Elsevier India Private Limited, Twenty second edition, 2015 page 433-445
9. William Boericke, Boerickes New Manual of Homeopathic Materia medica with Repertory, B Jain Publisher (P) Ltd, Second Revised and Re Augmented Edition: 2000, 35<sup>th</sup> Impression 2014, Page no Pg 203.
10. Kasper, Braunwald, Fauci, Hauser, Longo, Jameson, Harrison Principles of Internal Medicine, 16<sup>th</sup> Edition, The McGraw Hill Companies Inc. 2005, page No 2563, 2564.